

Clinical, Laboratory, and MRI Analysis of Cellulite Treatment with a Unipolar Radiofrequency Device

DAVID J. GOLDBERG, MD,*† AMIN FAZELI, MD,* AND ALEXANDER L. BERLIN, MD*

BACKGROUND Cellulite is seen in more than 85% of postpubertal women. Recent studies show that bipolar radiofrequency and low-level laser devices can produce mild skin tightening of cellulite.

OBJECTIVE The primary objective was to determine if a novel unipolar, more deeply penetrating, radiofrequency device can promote better skin tightening with fewer treatments than is seen with previously described devices. The secondary objective was to determine if such a deeply penetrating device produced undesired effects on lipid metabolism.

METHODS Thirty subjects, with Nurnberger-Muller Scale III–IV upper thigh cellulite, were entered into the study. All were treated, every other week, with a unipolar radiofrequency device for a total of six treatments. Subjects were evaluated before and 6 months after treatment with clinical photographs, clinical measurements, biopsies, MRIs, and blood lipid evaluations.

RESULTS Twenty-seven subjects showed evidence of clinical improvement. The mean decrease in leg circumference was 2.45 cm. Histologic changes showed dermal fibrosis of the upper dermis. No MRI or lipid abnormalities were noted.

CONCLUSION Upper thigh skin cellulite can be improved with a new unipolar radiofrequency device. Histologic changes suggest skin tightening as the method of improvement. No undesired complications of the skin or lipid metabolism were noted.

Alma Lasers (Buffalo Grove, IL) provided the laser and funding for this study.

Cellulite, with its characteristic orange peel skin irregularity and dimpling of the buttocks and thighs, is seen in more than 85% of postpubertal women.¹ Cellulite can actually be seen in infancy demonstrated by the pinch test, whereby the skin tethers the dermis to a deeper layer of connective tissue forcing groups of adipose tissue into the overlying skin. Predisposition toward cellulite appears to be related to gender, heredity, race, increasing age, and obesity.^{1–4}

Full-blown cellulite, generally presenting after adolescence, is characterized by permanent (as opposed to induced), obvious skin irregularity. A cellulite

clinical grading system has now been identified with grades varying between I and IV. Grades III and IV are the more typical presentations whereby skin dimpling is obvious in the standing position.

A variety of methods have been proposed to treat cellulite. Most produce either no results or short-lived improvement. Recent studies have documented the efficacy of both (1) a low-energy diode laser with associated contact cooling, suction and massage and (2) an infrared light/bipolar radiofrequency (RF) device combined with mechanical manipulation. Both systems involve biweekly treatments for 6 to 16 weeks. Results from both treatments appear to be similar.

*Skin Laser and Surgery Specialists of NY/NJ, New York, New York; †Department of Dermatology, Mount Sinai School of Medicine, New York, New York

© 2007 by the American Society for Dermatologic Surgery, Inc. • Published by Blackwell Publishing •
ISSN: 1076-0512 • *Dermatol Surg* 2008;34:204–209 • DOI: 10.1111/j.1524-4725.2007.34038.x

The current study was undertaken to determine the results of a new unipolar, volumetric RF device in the treatment of cellulite. Unipolar RF differs from other previously described RF devices in that it does not produce electrical current within tissue. Instead, high-frequency electromagnetic radiation at 40 MHz is produced by the device. The resulting rapidly alternating polarity of the electromagnetic field induces high-frequency rotational oscillations in the water molecules. Such ultrarapid oscillations produce heat, subsequently dissipated to the surrounding tissue. The phase of the electromagnetic waves produced by this device is controlled in such a way so as to allow for heat penetration into tissue to a depth of up to 15 to 20 mm. Thus, deeper skin structures can be effectively heated, resulting in the potential utility of this device for the treatment of cellulite.

The purpose of this study was to determine if such deep unipolar RF-induced heating could tighten the skin irregularities of cellulite with a manageable, every-other-week treatment schedule. In addition, because of the potential concern that such deep heating might impact on the body's lipid metabolism, pre- and posttreatment lipid analysis and MRIs (magnetic resonance imagings) were also undertaken.

Methods

Inclusion Criteria

Thirty subjects, over the age of 30, with a clinical cellulite gradation of 3 to 4 on the Nurnberger-Muller scale, were entered into the study. All subjects were using either acceptable contraception or were postmenopausal. All subjects signed an informed consent approved by the institutional review board of Pascack Valley Hospital (Westwood, NJ). The study protocol conformed to the guidelines of the 1975 Declaration of Helsinki.

Exclusion Criteria

Any potential subject with infection, dermatitis, or scarring in the treatment area; diabetes; pregnancy;

pacemaker or cochlear implant; and/or elevated pretreatment blood lipid analysis was excluded. Any potential subjects who, within 6 months before the start of the study, had received any treatment with a device designed for cellulite were excluded from the study.

Treatment Regimen

Subjects with upper thigh cellulite were treated every other week, for a total of six sessions, with a unipolar RF device (Alma Lasers, Buffalo Grove, IL). A total of 150 to 170 W of energy was delivered through a unipolar RF handpiece, with a cooled tip, for 30 seconds duration. Three such passes were undertaken so as to maintain a measured epidermal skin temperature of 40 to 42 C. No other cellulite treatments were allowed during the course of the study. Pre- and 6-month posttreatment weight measurements, standardized clinical photographs and clinical measurements, and skin and fat biopsies analyzed with hematoxylin and eosin, standard blood lipid analyses, and MRI analyses of the treated areas were undertaken.

Treatment Evaluations

Measurements of thigh circumference and visual and photographic grading were undertaken as previously described by Goldman.⁵ Standardized Canfield digital photography (Canfield Scientific, Fairfield, NJ) was utilized. Photographic evaluations were undertaken using a 1 to 4 scale based on leg smoothness (1 representing no improvement and 4 representing most improvement). The scores of two separate, nontreating scorers were averaged.

Measurement of upper thigh circumference was undertaken with the same tape measure in the same room location for every subject. The distance from the upper thigh to the designated floor spot was measured before initial treatments to serve as an identical reference spot to that measured location 6 months after treatment. Both thighs were treated and measured. An average of

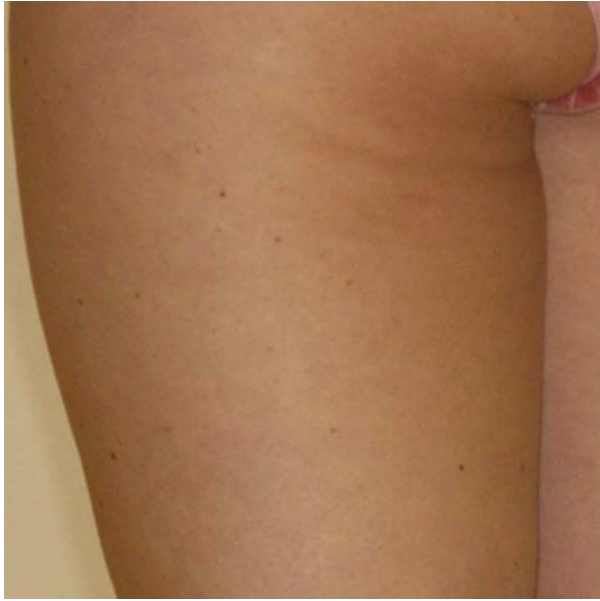

Figure 1. Cellulite before treatment with a unipolar radiofrequency device.

the two thigh measurements for each thigh was used.

Results

Twenty-seven of 30 treated subjects showed evidence of clinical improvement as measured by a nontreating evaluator (Figures 1 and 2). The mean decrease in leg circumference was 2.45 cm (1.2 in.). Graded improvement on the 1 to 4 scale was noted to be 2.9. No significant changes in posttreatment measured

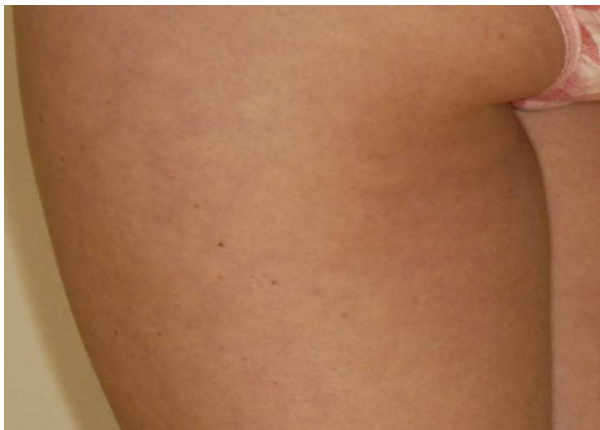

Figure 2. Tightening of skin 6 months after treatment.

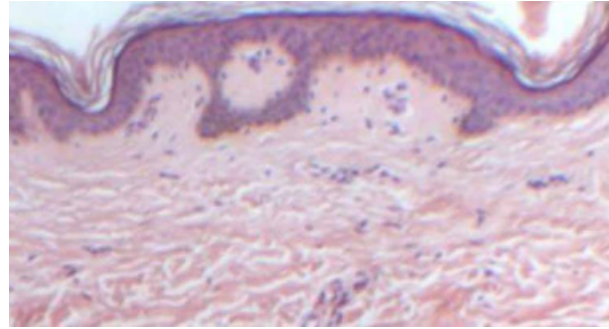


Figure 3. Pretreatment biopsy. Original magnification, $\times 20$.

weight or blood lipids were noted. Although post-treatment erythema was noted in all treated subjects for 30 to 120 minutes, no blistering, scarring, or pigmentary changes were seen. Histologic evidence of posttreatment dermal fibrosis, without any gross changes in the subcuticular layer, was noted (Figures 3 and 4). MRI did not reveal any gross changes in the pannicular layer (Figures 5 and 6).

Discussion

A wide variety of cellulite treatments are now available. Noninvasive massage therapies, including suction-based mechanical massage units, have

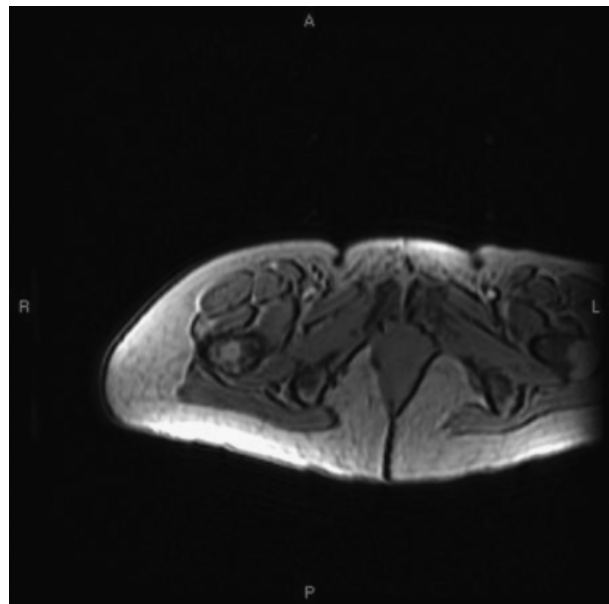


Figure 4. Posttreatment biopsy showing dermal fibrosis. Original magnification, $\times 20$.

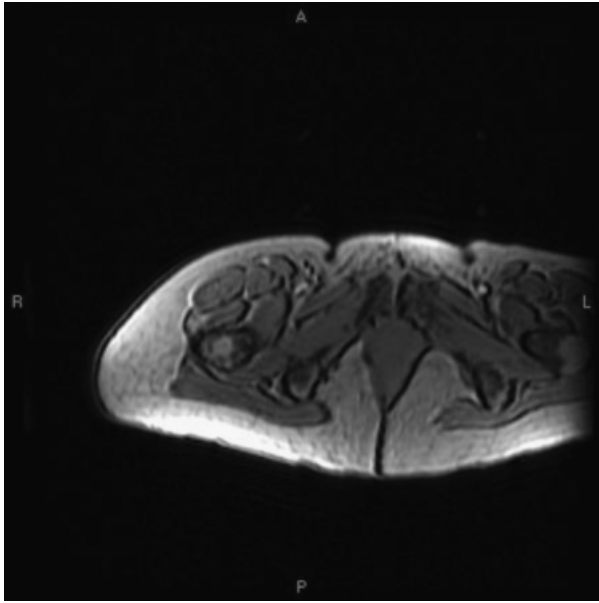


Figure 5. Pretreatment MRI.

shown variable, short-term results. Such mechanical suction induced results are thought to occur from the stretching of the treated vertical connective tissue and stimulation of lymphatic flow.⁶

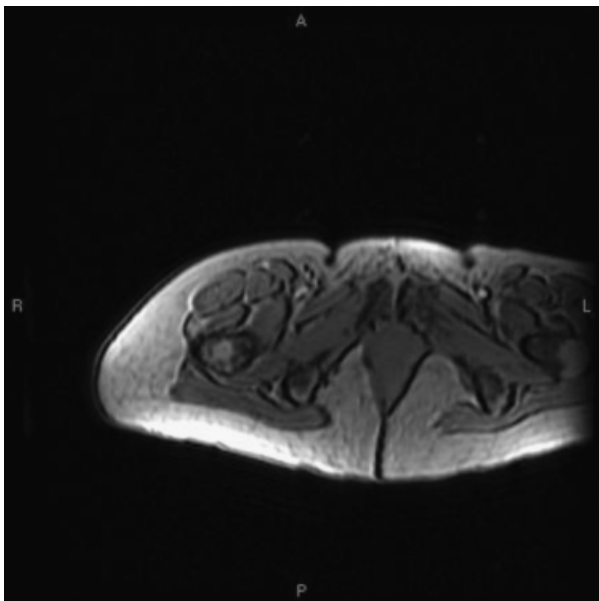


Figure 6. Posttreatment MRI. No changes are noted.

Collis and colleagues⁷ evaluated the efficacy of topical aminophylline cream and mechanical suction alone, and in combination, for thigh and buttock cellulite. They showed that no statistical difference existed in leg measurements in any posttreatment group.

A wide variety of dietary supplements have also been suggested to increase body metabolism and circulation while decreasing swelling. None are FDA-approved cellulite treatments.⁵

Surgical subcision has been noted to improve moderate to severe cellulite.⁸ The technique involves the insertion of a needle to interrupt the connective tissue adhesions that tether the dermis to the underlying fascia, thereby diminishing the lumpy skin appearance. Liposculpture has also been used to decrease the appearance of cellulite by reducing local fat volume and by disrupting the fibrous bands. The long-term clinical benefit of both these treatments is not known.

Mesotherapy is another highly popular treatment for cellulite. However, few studies substantiate the benefit of this approach. The technique involves a series of injections delivered into the subcutis. The solutions have included such compounds as aminophylline, hormones, enzymes, herbal extracts, vitamins, and minerals. The one ingredient most consistently utilized has been a soybean lecithin extract (phosphatidylcholine) that is responsible for lipolysis. The lack of a precise treatment protocol and the risk of localized adverse events, including edema, echymoses, tender subcutaneous nodules, infection, urticarial reactions, and irregular skin contours, has discouraged many from attempting this technique.^{9,10}

Focused ultrasound is also currently being evaluated for its role in improving cellulite. This approach may show efficacy through the emulsification of localized treated fat. Such an approach appears to have its benefit in the fatty layer and not via tightening of the overlying skin.

Previous studies have documented the efficacy of a low-level energy diode laser in conjunction with mechanical suction, as well as a bipolar RF, infrared light suction-based device for the treatment of cellulite.¹¹⁻¹³ Unfortunately many biweekly treatments are required; results can be modest. One would expect that the skin-tightening effects of unipolar RF would be deeper, and potentially greater, than that seen from more superficial RF devices. We noted improvement in almost all treated subjects 6 months after only six every-other-week treatments. This improvement appeared to be greater than that previously reported with bipolar and low-energy laser system. Our findings of dermal fibrous band thickening, as well as the previously reported ultrasound evidence of unipolar RF-induced contraction between the dermis and Camper's fascia,¹⁴ may explain the noted clinical tightening seen in our study. Where our study differed from that of del Pino and colleagues¹⁴ was the lack of any noted changes in our study in the pannicular layer, including Camper's fascia. Del Pino and colleagues noted that at 15 days after two monopolar RF treatments, 68% of treated subjects presented with a 20% contraction of the distance between the stratum corneum and Camper's fascia; our subjects, evaluated at 6 months after their last treatment, did not show these changes. This would suggest that, although monopolar RF may initially promote deep tightening, it is, at the end of 6 months, dermal fibrosis that leads to the longer lasting results.

Of concern for any cellulite treatment that may impact on fat is the effect of that technique on lipid metabolism. Because RF treatments generally have little to no effect on fat, we did not expect to see any changes in measured weights, blood lipid profiles, or MRI analysis of the fatty layer. This was borne out in our study.

Unipolar diffuse RF treatment represents a new approach to the tightening of cellulitic thighs. In general, fewer treatments and better results were noted compared to previous bipolar RF and low-energy

laser approaches. Although further studies comparing treatment of one thigh to another, rather than our study which looked at treatment of both thighs, should be undertaken, our study clearly documents the efficacy of monopolar RF treatments. What has yet to be determined is how long treatment results last and whether combined approaches, with other modalities, will lead to even better results.

Conclusion

Upper thigh cellulite can be improved with the use of a new noninvasive skin-tightening device that utilizes unipolar RF with epidermal contact cooling. Treatment results last at least 6 months.

References

1. Karnielli E. Glucose transport in rat and human adipose tissue. In: Illouz YG, Devillers YT, editors. *Body sculpturing by lipoplasty*. Edinburgh: Churchill Livingstone; 1988. p. 457-67.
2. Kligman AM. Cellulite: facts and fiction. *J Geriatr Dermatol* 1997;5:136-9.
3. Curri SB. Cellulite and fatty tissue microcirculation. *J Cosmet Toilet* 1993;108:51-58.
4. Leibaschoff GH. Cellulite (liposclerosis): etiology and treatment. *Am J Cosmet Surg* 1997;14:395-401.
5. Goldman MP. Cellulite: a review of current treatments. *Cosmet Dermatol* 2002;15:17-20.
6. Chang P, Wiseman J, Jacoby T, et al. Noninvasive mechanical body contouring (Endermologie): a one-year clinical outcome study update. *Aesthetic Plast Surg* 1998;22:145-53.
7. Collis N, Elliot LE, Sharpe C, et al. Cellulite treatment: a myth or reality: a prospective randomized, controlled trial of two therapies, Endermologie and aminophylline cream. *Plast Reconstr Surg* 1999;104:1110-7.
8. Hexsel DM, Mazzuco R. Subcision: a treatment for cellulite. *Int J Dermatol* 2000;39:539-44.
9. Rotunda AM, Suzuki H, Moy RL, et al. Detergent effects of sodium deoxycholate are a major feature of an injectable phosphatidylcholine formulation used for localized fat dissolution. *Dermatol Surg* 2004;30:1001-9.
10. Hexsel D, Serra M, Mazzuco R, et al. Phosphatidylcholine in the treatment of localized fat. *J Drugs Dermatol* 2003;2:511-8.
11. Alster T, Tanzi EL. Extended experience with a novel combination radiofrequency, infrared light and mechanical tissue manipulation device for the treatment of cellulite. *J Cosmetic Laser Ther* 2005;7:81-5.
12. Sadick NS, Mulholland RS. A prospective clinical study to evaluate the efficacy and safety of cellulite treatment using the combination of optical and RF energies for subcutaneous

tissue heating. *Journal Cosmetic Laser Ther* 2004;6:187–90.

13. Nootheti PK, Magpantay A, Yosowitz G, et al. A single center, randomized, comparative, prospective clinical study to determine the efficacy of the VelasMOOTH system versus the Triactive system for the treatment of cellulite. *Lasers Surg Med* 2006;38:908–12.
14. Del Pino E, Rosado RH, Azuela A, et al. Effect of controlled volumetric tissue heating with radiofrequency on cellulite and the

subcutaneous tissue of the buttocks and thighs. *J Drugs Dermatol* 2006;5:714–22.

Address correspondence and reprint requests to: David J. Goldberg, MD, Skin Laser and Surgery Specialists of NY/NJ, 115 E. 57th Street, Suite 710, New York, NY 10016, or e-mail: drdavidgoldberg@skinandlasers.com

COMMENTARY

Cellulite is a perplexing condition of tremendous consumer interest. Notice that I term cellulite a “condition” rather than a “disease,” since it is hard to claim that treatment is required for something that affects 85% of postpubertal women, as indicated by the authors. A variety of therapies have been put forth for cellulite treatment ranging from exercise to weight loss to vibrating machines to suction devices to mesotherapy to surgical subcision to infrared light to the current study utilizing unipolar radiofrequency. This plethora of treatments should tell the physician something significant about cellulite treatment. None of the therapies work very well. This study made a scientific attempt to understand exactly what is happening in the skin to produce an improvement in the appearance of cellulite after six every-other-week radiofrequency treatments. A limitation of the study is that no control group was included and a sham treatment group might have changed the results. Nevertheless, the most significant finding was the production of dermal fibrous band thickening. This might explain the continued observed cellulite improvement 6 months after treatment. Yet, the radiofrequency induction of scarring is a little concerning. What happens as the subcutaneous fat is lost in maturity? Will there be unusual dimples or contour problems in a woman who underwent this therapy in her 20s and who is now in her 70s? Since the induction of scarring is permanent, these long-term questions deserve consideration in the mind of the dermatologist. Is there such a thing as an appearance-enhancing scar? The current work indicates that this dermal fibrous band thickening may decrease the herniation of the fat into the dermis and improve the dimpled appearance of cellulite. In the end, it is perhaps unfortunate that cellulite is not considered attractive, since it is much easier to induce than to ameliorate.

ZOE DIANA DRAELOS, MD
High Point, NC